



Cardiac Rhabdomyoma In Familial Tuberous Sclerosis

Amit Kumar Chaurasia*, S Harikrishnan, S Bijulal, Dinesh Choudhary, Tharakan JA

Department of Cardiology, Sree Chitra Tirunal Institute for Medical Sciences and Technology, Trivandrum 695 011, India

ARTICLE INFO

Article Type:

Case Report

Article History:

Received: 1 May 2013

Accepted: 10 June 2013

Keywords:

Rhabdomyoma

Tumor

Right Ventricle

Tuberous Sclerosis

ABSTRACT

Cardiac rhabdomyomas are often associated with tuberous sclerosis in infants. We report a 5 month old child presented with a tumor in the right ventricle and echocardiography features of rhabdomyoma. Both the child and her father had cutaneous features of tuberous sclerosis. In the absence of features of congestive heart failure, surgery is rarely required.

Introduction

Primary cardiac tumors are rare in children. The most common primary cardiac tumors in infants are rhabdomyomas and Fibromas.¹ Rhabdomyoma is usually associated with tuberous sclerosis (TS). We report a case of cardiac rhabdomyoma in a 5 month old infant with cutaneous features of tuberous sclerosis.

Case Report

A 5 month old child was referred for evaluation of a systolic murmur. The child had features of tuberous sclerosis in the form of ash leaf macules (Figure 1), but no other central nervous system or cutaneous features. Both the optic fundi were normal. On examining the child's father, adenoma sebaceum (Figure 2) and multiple ash leaf macules were evident.

Echocardiographic examination performed showed a large mass in the right ventricle (RV) occupying the outflow tract (RVOT) (Figure 3). The child did not have any cardiac symptoms.

The father did not have any evidence of intra-cardiac tumor on echocardiography and the central nervous system examination was normal.

Since the child had no features of valvular obstruction, arrhythmias or CHF, the parents were advised to follow up regularly. Echocardiogram performed after 4 months showed that there was a significant regression in the size of the tumor.

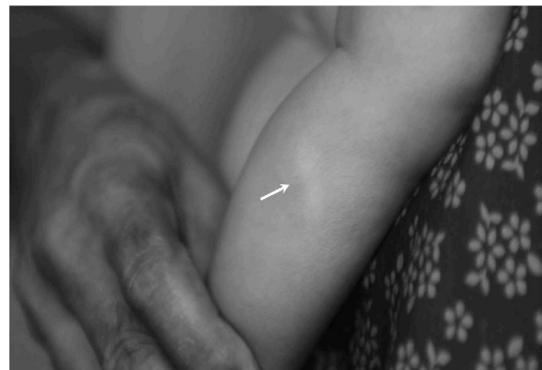

Figure 1. Lower limb of the child showing ash leaf hypopigmented macules

Discussion

Rhabdomyomas are the most common cardiac tumor in infancy.¹ They are usually associated with TS. TS is eventually diagnosed in 52-86 % of patients with rhabdomyomas.² Conversely, 50% of children with tuberous sclerosis have rhabdomyomas on echocardiographic evaluation. The clinical manifestations of TS may appear later in life.³

Although no biopsy could be performed, a diagnosis of rhabdomyoma was based on the fact that the mass was highly echogenic, well circumscribed and homogenous without calcification, spontaneously regressing with time. The cutaneous features of tuberous sclerosis in the form of

*Corresponding author: Amit Kumar Chaurasia, E-mail: amitkumarchaurasia@gmail.com

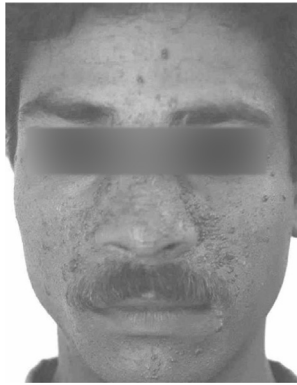


Figure 2. Face of the patients' father showing adenoma sebaceum

adenoma sebaceum and patches confirmed the diagnosis. The natural history of large rhabdomyomas shows regression in or disappearance with time.^{4,5} The presence of a mass alone is not an indication for surgery. In the presence of life threatening intractable arrhythmias, valvular obstructions or other hemodynamic compromise, surgery is indicated.⁶⁻⁸

Since the index case was asymptomatic and did not have any hemodynamic disturbance due to the tumor, the preferred course of action was an observatory one.

TS is an autosomal dominant disease.³ The case under discussion also presented similar inheritance. Heredity is evident only in a minority of cases.

natural history of cardiac rhabdomyoma with and without tuberous sclerosis. **Acta Paediatr** 1996;85:928-31.

3. Maurice V, Ropper AH. *Adams and Victor's Principles of Neurology*. New York: McGraw-Hill ; 2001.

4. Smythe JF, Dyck JD, Smallhorn JF, Freedom RM. Natural history of cardiac rhabdomyoma in infancy and childhood. **Am J Cardiol** 1990;66:1247-9.

5. Alkalay AL, Ferry DA, Lin B, Fink BW, Pomerance J. Spontaneous regression of cardiac rhabdomyoma in tuberous sclerosis. **J Clin Paediatr** 1987;26:532-5.

6. Jacobs JP, Konstantakos AK, Holland FW, Herkowaski K, Ferrer PL, Perryman RA. Surgical treatment of cardiac rhabdomyomas in children. **Ann Thorac Surg** 1994;58:1552-5.

7. Fenoglio JJ Jr, McAllister HA Jr, Ferrans VJ. Cardiac rhabdomyoma: A clinicopathologic and electron microscopic study. **Am J Cardiol** 1976;38:241-51.

8. Nir A, Tajik AJ, Freeman WK, Seward JB, Offord KP, Edwards WD, Mair D, et al. Tuberous sclerosis and cardiac rhabdomyoma. **Am J Cardiol** 1995; 76:419-421.

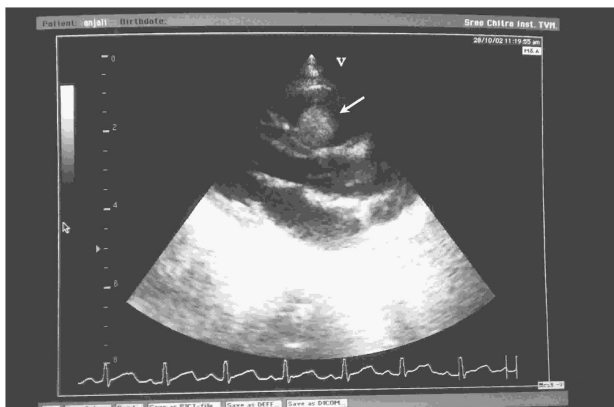


Figure 3. Echocardiogram picture (Parasternal long axis view) showing tumor in the right ventricle (arrow)

Ethical issues: The study has been approved by the ethic committee at the Institute.

Competing interests: None.

References

1. Becker A.E. Primary Heart Tumors in the Pediatric Age Group: A Review of Salient Pathologic Features Relevant for Clinicians. **Pediatr Cardiol** 2000; 21:317-23.
2. Bosi G, Lintermans JP, Pellegrino PA, Svaluto-Moreolo G. The