



Giant Mediastinal Thymolipoma in 35-Year-Old Women

Manuchehr Aghajanzadeh^{1*}, Ali Alavi², Zahra Pourrasouli³, Gilda Aghajanzadeh³, Sara Massahnia³

¹Department of Thoracic Surgery, Razi Hospital, Guilan University of Medical Sciences, Rasht, Iran

²Department of Pulmonology, Razi Hospital, Guilan University of Medical Sciences, Rasht, Iran

³Respiratory Diseases & TB Research Center of Guilan University of Medical Sciences, Razi Hospital, Rasht, Iran

ARTICLE INFO

Article Type:
Case Report

Article History:
Received: 6 January 2011
Accepted: 2 Feb 2011
ePublished: 28 May 2011

Keywords:
Mediastinum
Myoid
Thymolipoma
Thymus

***Corresponding Author:**
Manuchehr Aghajanzadeh,
Tel: +98 (131) 5542460,
Fax: +98 (131) 5542460,
E-mail: smassahnia@yahoo.com

Copyright © 2011 by Tabriz University
of Medical Sciences

ABSTRACT

The patient was 35-year-old women with a six-month history of difficulty breathing and chest pain. An anterior-posterior chest radiograph revealed a widened mediastinum with small lung volumes. During his diagnostic evaluation, a computed tomographic scan was performed and with huge mass in the anterior mediastinum with extension to the left and right side of pleural space. With postero-lateral thoracotomy the huge mass was resected. The patient discharged with good condition.

Introduction

Thymolipomas are rare anterior mediastinal tumors composed of mature adipose tissue and benign thymic tissue arising from thymus gland. This tumor accounts for only a small percentage of mediastinal masses.^{1,2} The majority of these tumors are clinically quiescent; however, symptomatic patients may present with myasthenia gravis, upper respiratory tract infections, dyspnea, tachypnea, and chest pain.^{3,4} Thymolipomas are benign neoplasms for which complete surgical excision is curative.

Case Report

The patient was a 35-year-old woman with a six-month history of difficulty breathing and chest pain. Because of increased dyspnea, she was admitted in hospital. She did not smoke and had no known occupational exposure. An anterior-posterior chest radiograph revealed a severe widened mediastinum with small lung volumes. Pulmonary function tests showed a decrease in forced vital capacity (47% predicted) and forced expiratory volume (42% predicted) with a total lung capacity of only 72%. These findings were

interpreted as being consistent with mixed obstructive and restrictive lung disease. During his diagnostic evaluation, a computed tomographic scan was performed. There was a huge mass in the anterior mediastinum overlying the heart with extension into the left and right hemithorax, predominantly consisting of fat with scattered linear soft tissue (Figure 1 and 2).

In left side postero-lateral thoracotomy, a large, encapsulated, vaguely lobulated mass weighting 1460g was found within the anterior mediastinum, and resected completely. In cut section, it was primarily consisted of mature-appearing adipose tissue with no area of hemorrhage or necrosis (Figure 3,4 and 5). The mass occupied approximately 80% of left and 50% of right pleural cavity, resulted in marked compression of posterior and inferior of right and left lungs. Histological examination revealed that the tumor was predominantly composed of lobules of mature adipose tissue intermixed with septa of thymic tissue containing abundant Hassall's corpuscles. In addition, the mass contained numerous polygonal myoid cells that were distributed and localized predominantly in the interface of thymic tissue and adipose lobules. The patient discharged in a good condition on 6th day after surgery. She had no problem until 18 month follow up.

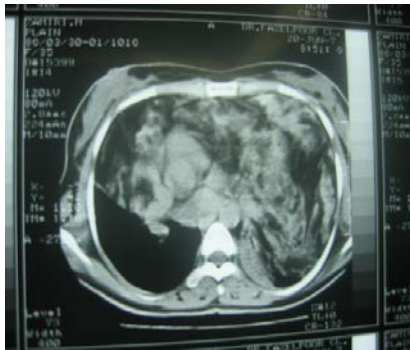

Figure 1. CT- Scan with Mediastinal Window with Huge Mass Which Filled Both Pleural Space.

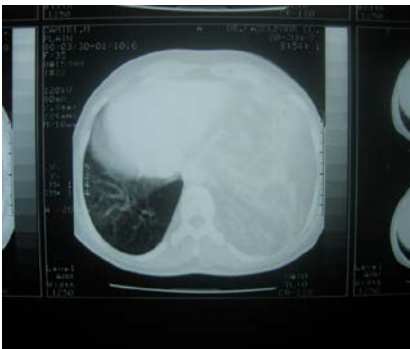

Figure 2. CT- scan with parenchyma window with huge mass which filled both pleural space.

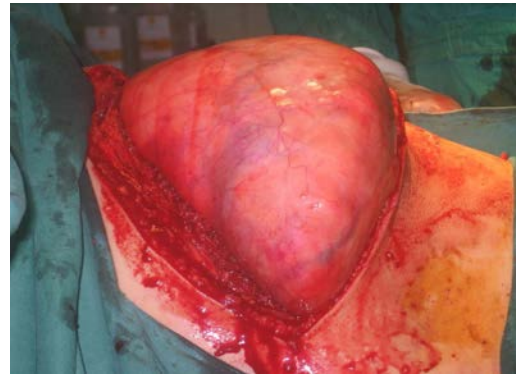


Figure 3. A huge mass during Thoracotomy was presented.

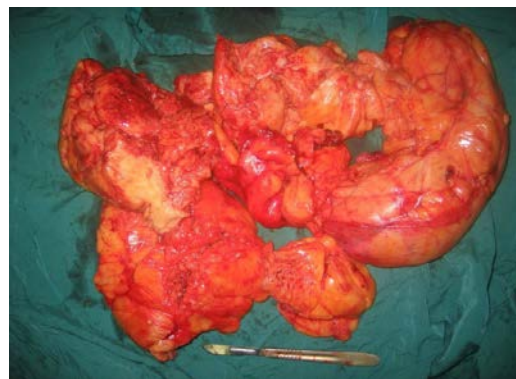

Figure 4. A huge mass after complete resection was presented.

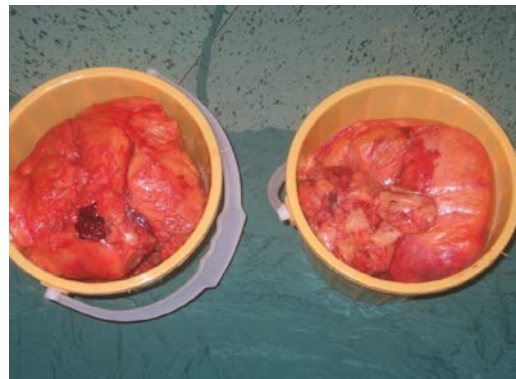


Figure 5. A huge mass after complete resection was presented

Discussion

Thymolipoma is a very rare mediastinal tumor composing mature adipose and thymic tissue arising from thymus gland. It is a rare and benign mesenchymal tumor of mediastinum that is often asymptomatic.⁵ This tumor accounts for only a small percentage of mediastinal.^{1,2} Clinically, most thymolipomas are identified incidentally during a diagnostic workup for other medical problems, although some nonspecific signs

like upper respiratory infection, chest pain, dyspnea, tachypnea, and chronic nonspecific chest symptoms have been identified at the time of presentation.³ Thymolipomas have been reported to be associated with certain autoimmune medical conditions, such as graves' disease and myasthenia gravis.^{1,6} On computed tomographic scan, the most common patterns seen in thymolipomas are linear whorls of soft tissue intermixed with fat or predominantly fat with scattered linear soft tissue attenuation. Radiographically, thymolipomas may be confused with more common lesions, such as mediastinal teratomas, thymic hyperplasia, lipomas, and cardiomegaly.⁷

This broad radiologic differential diagnosis stresses the need for histologic evaluation in the diagnosis of anterior mediastinal masses. Anterior mediastinal liposarcomas have been described and liposarcomas of thymic origin do exist.⁸ Mediastinal liposarcomas may grossly resemble benign thymolipomas and may be associated with thymic tissue.⁸ Grossly, most thymolipomas are lobulated and encapsulated, range in size from 4 to 36 cm, and consist of yellow adipose tissue with no areas of hemorrhage and necrosis.⁷ Histologically, thymolipomas have a varying proportion of mature adipose and thymic components. In this case, the thymolipoma consisted of predominantly mature adipose tissue with scattered elongated aggregates and small round nodules of atrophic thymic epithelium embedded within fat. No lipoblast was identified. In one section of the tumor, reminiscent of myoid cells, was identified within the mature fat. Such clusters of myoid cells have been reported previously in thymolipomas⁹ such as present case, some thymolipomas show predominantly mature adipose tissue with only occasional remnants of thymic tissue. However, other thymolipomas have been reported to have a greater proportion of thymic tissue.^{3,5,7}

The histologic differential diagnosis for thymolipomas includes lipoma, well-differentiated liposarcoma, and thymic hyperplasia.³ The distinction between a lipoma and a predominantly fatty thymolipoma may be difficult. In the latter, extensive sectioning and immunohistochemical, staining for cytokeratin may highlight thymic epithelial elements in a thymolipoma. Liposarcomas typically have scattered nuclear atypia, lipoblasts, and no thymic epithelium. Thymic hyperplasia classically has unremarkable thymic architecture without presence of abundant adipose tissue. Thymolipomas may adhere to the adjacent structures and displace organs within the chest cavity, but invasion into adjacent structures has not been documented in the literature. The encapsulated and lobular nature of thymolipomas and lack of invasion into adjacent structures usually allow for a relatively uncomplicated

surgical excision of the tumor. Our case represents an atypical clinical presentation of a giant thymolipoma. Eighty percent of thymolipomas present within the first 4 decades of life. Thymolipomas are often asymptomatic and are identified incidentally after diagnostic evaluation for nonspecific respiratory symptoms.^{9,10}

In our case, the patient had long-standing respiratory complaints, which appears to have been directly caused by thymolipoma. The compression of the right and left lung by the thymolipoma in our case resulted in increased pulmonary parenchyma resistance and reduced lung volume. The reduced lung volume resulted in chronic respiratory symptoms and a primarily restrictive lung pattern. The chronically increased pulmonary vascular resistance led to development of pulmonary hypertension, cor pulmonale, heart failure, and ultimately death.^{4,10}

This case highlights an atypical presentation of a thymolipoma, a rare, benign thymic tumor which can achieve a massive size, occasionally resulting in respiratory symptoms and death. Thymolipomas are benign neoplasms for which complete surgical excision is curative as our case.^{9,10}

Ethical issues: The study was approved by the Ethical Committee of the University.

Conflict of interests: No conflict of interest to be declared.

References

1. Reintgen D, Fetter BF, Roses A, McCarty KS Jr. Thymolipoma in association with myasthenia gravis. *Arch Pathol Lab Med* 1978; 102:463-466
2. Argani P, de Chiocca IC, Rosai J. Thymoma arising with a thymolipoma. *Histopathology* 1998; 32:573-574.
3. Moran CA, Rosado-de-Christenson M, Suster S. Thymolipoma: clinicopathologic review of 33 cases. *Mod Pathol* 1995; 8:741-744.
4. Iseki M, Tsuda N, Kishikawa M, Shimada O, Hayashi T, Kawahara K, Tomita M. Thymolipoma with striated myoid cells. Histological, immunohistochemical, and ultrastructural study. *Am J Surg Pathol* 1990;14:395-398.
5. Moran CA, Zeren H, Koss MN. Thymofibrolipoma: a histologic variant of thymolipoma. *Arch Pathol Lab Med* 1994;118:281-282.
6. Le Marc'hadour F, Pinel N, Pasquier B, Dieny A, Stoeber P, Couderc P. Thymolipoma in association with myasthenia gravis. *Am J Surg Pathol* 1991;15:802-809.
7. Rosado-de-Christenson ML, Pugatch RD, Moran CA, Galobardes J. Thymolipoma: analysis of 27 cases. *Radiology* 1994;193:121-126.
8. Sung MT, Ko SF, Hsieh MJ, Chen YJ, Chen WJ, Huang HY. Thymoliposarcoma. *Ann Thorac Surg* 2003; 76:2082-2085.

9. Gannon BR, Dexter DF, Petsikas D, Isotalo PA. Mediastinal Thymolipom: a rare occurrence with striated myoid cells. *Tumori* 2007;93: 198-200.

10. Pai KR, Irvine R. Pathologic quiz case: giant mediastinal mass in a 69-year-old man. Thymolipoma. *Arch Pathol Lab Med* 2004; 128:e159-160.