Lotfi-Sadigh S, et al, ***J Anal Res Clin Med,*** 2015, 3(1): 56-61.
doi: 10.5681/jarcm.2015.009, *http://journals.tbzmed.ac.ir/JARCM*

Original Article

Clinical predictors of abnormal computed tomography scan in minor head trauma in children under 2 years old

Sepideh Lotfi-Sadigh[1], Changiz Gholipour[2], Samad Shams-Vahdati*[3], Rouzbeh Rajaei-Ghafouri[4], Ardalan Golbahar-Haghighi[1]

[1] *Student of Medicine, Tabriz University of Medical Sciences, Tabriz, Iran*
[2] *Associate Professor, Road Traffic Injury Research Center, Department of Surgery, Tabriz University of Medical Sciences, Tabriz, Iran*
[3] *Assistant Professor, Road Traffic Injury Research Center, Department of Emergency Medicine, Tabriz University of Medical Sciences, Tabriz, Iran*
[4] *Assistant Professor, Department of Emergency Medicine, Tabriz University of Medical Sciences, Tabriz, Iran*

Article info
Article History:
Received: 03 Sep. 2014
Accepted: 09 Oct. 2014
ePublished: 12 March. 2015

Keywords:
Children,
Mild Blunt Head Trauma,
Emergency Department,
Computed Tomography

Abstract
Introduction: Minor blunt head trauma is a common reason for children to present to the emergency department (ED). Crania computed tomography (CT) is the choice for evaluating children with blunt head trauma in the ED, but few shows abnormal findings. In this study, we aim to evaluate CT findings in children with blunt head trauma and clinical symptoms to identify clinical predictors of abnormal CT scans.
Methods: In this prospective study, 218 children under 2 years of age (121 male and 97 female with mean age of 11.24 ± 4.31 months) with compliant of minor blunt head trauma visiting the ED between April 2011 and April 2014 were included. Physical examination and clinical symptoms, as well as CT findings and patients' outcome were evaluated.
Results: Physical examinations were normal in 95.9%, and clinical symptoms were present only in 25.7% including vomiting in 16.1%, loss of consciousness (LOC) in 8.3%, ear/nose bleeding in 4.1% and seizure in 5.5%. CT scan was requested in 189 cases (86.7%) of which, 7.9% were abnormal including linear fracture in 5.3%, subgaleal hematoma in 1.1% and depressed fracture, subcutaneous hematoma and intracranial hemorrhage (ICH) each in 0.5%. Among all cases, 89.0% were discharged from ED with no further observation, 6.0% discharged after 48 h observation and 5.0% were hospitalized. There was a significant correlation between abnormal CT findings and having any clinical symptoms, vomiting and Ear/nose bleeding.
Conclusion: In children under 2 years old with minor blunt head trauma, most CT scans are unnecessary. Considering clinical symptoms as predictors of abnormal CT scans we can reduce unnecessary ones.

Citation: Lotfi-Sadigh S, Gholipour Ch, Shams-Vahdati S, Rajaei-Ghafouri R, Golbahar-Haghighi A. **Clinical predictors of abnormal computed tomography scan in minor head trauma in children under 2 years old.** J Anal Res Clin Med 2015; 3(1): 56-61.

Introduction

Traumatic brain injury (TBI) is a significant cause of mortality and morbidity in children.[1] Minor closed head injury is one of the most common complaint of children refer to the ED.[2] Low proportion of children refer to the ED require neurosurgical intervention.[3-5] In children with minor head trauma, appropriate physical and neurologic examination should be performed.[6]

An unenhanced computed tomography scan (CT scan) of the brain is choice modality of minor head trauma in children under 3 years old because of two reasons: 1. most of the patients have no or minimal symptoms. 2. Neurological examination is difficult in children under 3 years old.[7-10] Brain CT scan confirms the diagnosis of TBI in less than 10.0%

*** Corresponding Author:** Samad Shams-Vahdati, Email: sshamsv@yahoo.com

of children with minor head trauma. Still, it is the choice for evaluation of children with head trauma.[3-5,9] Besides, CT scan is an expensive imaging modality and put the patient at increased risk of malignancy.[11-14]

Although avoiding unnecessary CT scans should be mentioned as a fact, brain CT scan is needed to minimize the risk of missing potentially dangerous TBIs with clinical symptoms.[15,16] Currently, there is no evidence-based guideline for radiologic evaluation in children with minor head trauma.[3,17-19]

The goal of this study is to identify some clinical symptoms as risk factors that could predict potentially dangerous TBI after minor head trauma that lead to decrease unnecessary CT scans.

Methods

In this prospective study, 218 children under 2 years of age with compliant of minor blunt head trauma visiting the ED of Imam Reza Hospital, Tabriz, Iran between April 2011 and April 2014 were included. Children with minor blunt head trauma, defined by a Glasgow coma scale score of 14 or 15, who were seen at the ED within 24 h of the traumatic event, were included. Patients with trivial injury mechanisms, defined a priori as ground level falls or as walking or running into stationary objects, and with no signs or symptoms of head trauma other than scalp abrasions or lacerations were excluded. Also, patients with penetrating trauma, comorbidities (ventricular shunts or bleeding disorders), or previous neuroimaging, as well as those who left the ED against medical advice were excluded from the study. The study protocol was approved by the Ethics Committee of Tabriz University of Medical Sciences and parents of all subjects gave written informed consent.

A standardized data collection survey was completed by an emergency medicine-trained attending or fellow physicians before cranial CT. Information about age, gender, type of trauma, physical and neurological examination findings, CT result, and last status (discharge, hospitalization, or referral) was obtained from patients' hospital case notes. An experienced radiologist interpreted cranial CT images who did not know the clinical data. Also, investigators conducted telephone surveys of a parent or guardian of children to get patients' outcome information within 30 days after their ED visits. Finally, all information was reviewed by an emergency physician to assess the CT results and blunt trauma outcome.

All data were analyzed using the SPSS software for Windows (version 17, SPSS Inc., Chicago, IL, USA). Baseline data are reported as means ± standard deviation (SD) (continuous data) or percentages (categorical data), depending on the data level. The correlation between clinical symptoms and CT findings were evaluated using Pearson's correlation. A $P < 0.050$ was considered as statistically significant.

Results

In this study, 218 children under 2 years old with blunt head trauma were evaluated. Table 1 demonstrates demographic profile of patients. Most of the children were male. The most common cause of an accident falls. Normal physical examination and negative clinical symptoms were seen in most cases. Vomiting was the most common clinical symptom. There was no black eye and raccoon sign in any cases. Neurological findings also were present only in 2 cases (0.9%). Abnormal findings in CT scan were seen in 7.9% including linear fracture in 10 cases (5.3%), subgaleal hematoma in 2 cases (1.1%) and depressed fracture, subcutaneous hematoma and intracranial hemorrhage (ICH) each in 1 case (0.5%) (Figure 1).

Among all cases, 194 (89.0%) were discharged from ED with no further observation, 13 (6.0%) were discharged after 48 h observation and 11 (5.0%) were hospitalized. All 29 cases (13.3%) with normal findings for which CT scan was not requested were discharged from ED. Among patients with available CT scans, 158 cases (90.8%) with normal CT scans and 7 cases (46.7%) with abnormal CT findings were discharged with no observation, 11 cases (6.3%) with normal and 2 cases (13.3%) with

abnormal CT findings were discharged after 48 h observation and 5 cases (2.9%) with normal and 6 cases (40.0%) with abnormal CT findings were hospitalized.

Table 1. Demographic profile of patients

Parameter	n (%)
Age (months) (mean ±)	11.24 ± 4.31
Males	121 (55.5)
Mechanism of injury	
Falls	161 (73.8)
Car accidents	30 (13.8)
Unknown	27 (12.4)
Physical examination	
Normal	209 (95.9)
Laceration	6 (2.75)
Swelling	1 (0.45)
Ecchymosis	1 (0.45)
Erythema	1 (0.45)
Clinical symptoms	56 (25.7)
Vomiting	35 (16.1)
LOC	18 (8.3)
Ear/nose bleeding	9 (4.1)
Seizure	12 (5.5)
Requested CT scan	189 (86.7)
Normal	174 (92.1)
Abnormal	15 (7.9)

CT scan: Computed tomography scan
LOC: Loss of consciousness; SD: Standard deviation

In 30 day follow-up, there were no deaths or worsening of patients' condition in need of hospitalization or intensive care.

Table 2 demonstrates the correlation between clinical symptoms and CT findings. There was a significant correlation between showing abnormal CT findings and having any clinical symptoms, vomiting and ear/nose bleeding. But the correlation between abnormal CT findings and loss of consciousness (LOC) and seizure was not significant.

Discussion

Minor head trauma is common among the pediatric population. Although it is a common presentation among children referred to ED, 3-5% of those have TBI, and only less than 1% of these children require neurosurgical intervention.[20,21] Zhu et al. showed that minor head trauma in boys is likely more common than in girls [69.2% vs. 30.8% of total mild TBIs (MTBIs) cases].[22] A similar report from Peloso et al. showed that head injury with symptoms of concussion is twice more in boys than girls.[23] Willer et al. also reported the same result in which boys suffer an MTBI more likely than girls.[24]

According to Elgmark et al. there is no significant difference between boys and girls in terms of what activities that caused a

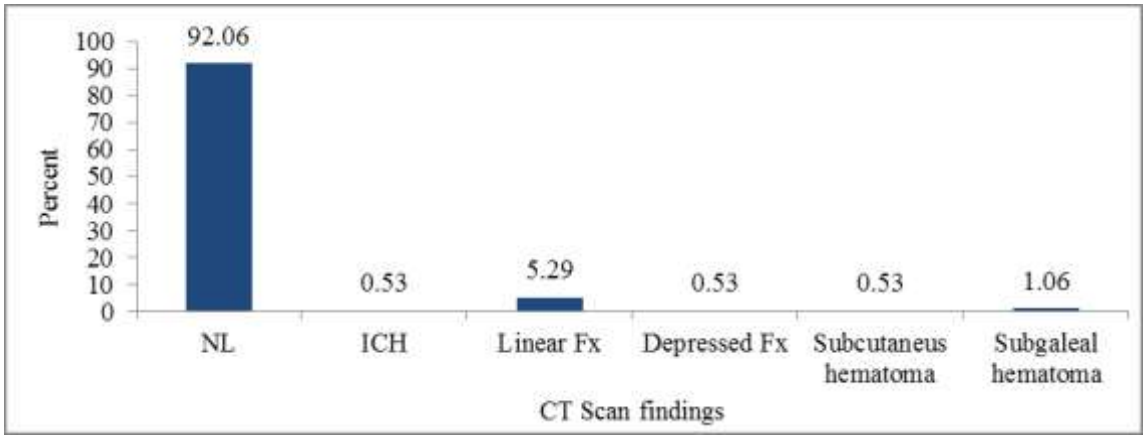

Figure 1. Computed tomography scan findings
NL: Neurological; ICH: Intracranial hemorrhage

Table 2. Correlation between clinical symptoms and CT scans findings

Variable	Pearson's correlation (r)	P
Having any clinical symptoms	-0.152	0.030
Vomiting	-0.162	0.020
Ear/nose bleeding	-0.210	0.004
LOC	-0.100	0.150
Seizure	-0.080	0.250

CT: Computed tomography; LOC: Loss of consciousness

MTBI.[25] In this study, of the 218 children, 121 (55.5%) were male and 97 (44.5%) were female.

Although cranial CT is the choice diagnostic modality for evaluation of children with blunt head trauma, it has its own disadvantages like increased risk of lethal malignancy and it's cost, studied by Brenner et al.[11] Palchak et al.[4] reported that 62.0% of children referred to ED with minor head trauma were evaluated with CT and only 7.7% of those reveal abnormal findings. Unlike these findings in another study by Zhu et al., they reported that 96.9% of children with minor head trauma were evaluated with CT scan, and 33.3% had abnormal CT findings.[22]

In minor head trauma, which constitutes about 90.0% of children with head trauma, the management of these patients is not easy, and there are no widely accepted, evidence-based guidelines.[2,3,17-19] It is important to identify predicating factors that could predict TBI that may help us to decrease unnecessary CT Scans. In this study, we observed 95.9% patients have normal physical examination. Clinical symptoms were seen in 25.7% of cases including: vomiting (16.1%), LOC (8.3%), ear/nose bleeding (4.1%), and seizure (5.5%). Post traumatic amnesia is an important predictor factor, however, it is difficult to evaluate, so we did not include this variable. There was a significant correlation between abnormal CT scan finding and clinical symptoms such as: vomiting, ear/nose bleeding, and no significant correlation with LOC and seizure.

In some of the previous studies, some clinical symptoms introduce as predicting factors of abnormal CT findings. Munivenkatappa et al. reported that in the presence of each symptoms such as vomiting, LOC, ear/nose bleeding and seizure patient should be evaluated by brain CT scan.[26] Gulsen et al. reported strong relationship between vomiting and presence of abnormal findings in brain CT scan.[27] However, Dunning et al. reported that there is no significant relationship between post traumatic vomiting and TBI.[19] Also Osmond et al. claimed that vomiting could not be considered as an indicator factor for performing CT scan.[5] Da DL et al. claimed that post-traumatic vomiting (PTV) is highly related to personal or familial background rather than presence of intracranial lesions.[28]

LOC is one of the clinical symptoms and may be presented in children with minor head trauma. Some previous studies have failed to show that history of LOC is predictor of TBI.[17,29-34] Davis et al.[35] claimed that LOC is not predictive of significant brain injury in children with minor head trauma the same as Falimirski et al.[36] reported. Palchak et al. claimed that an isolated LOC, or isolated LOC and/or amnesia without any other clinical symptoms like vomiting, seizure, new onset headache, radiologic signs of skull fracture, altered mental status, neurologic deficit, and scalp hematoma is not related to presence of abnormal finding in brain CT scan.[4] On the other hand, some previous studies identified LOC as predictor of abnormal findings in brain CT scan of children with minor head trauma.[20,37-43] Dunning et al. also reported that there is a statistical relation between LOC and TBI.[19] In our study, LOC was seen in 18 cases (8.3%) and correlation between LOC and abnormal CT findings was not significant.

In our study, we did not find a significant correlation between post traumatic seizure (PTS) and abnormal brain CT scan. Dias et al. also reported that children with simple PTS without any history of neurologic disorder and consumption of antiepileptic drugs had not abnormal CT scan.[44] Saboori et al. identified PTS as predictor of having abnormal CT scan.[45] Dunning et al. claimed that the presence of seizures showed a trend toward an association with brain injury after minor trauma but is not statistically significant correlation.[46]

It seems that some clinical symptoms as mentioned above (PTV, PTS, LOC, and ear/nose bleeding) could be considered as risk factors that could predict presence of abnormal CT findings in children under 2 years old with minor head trauma. These clinical risk factors could help us decide which patient needs brain CT scan as further evaluation and possibly

neurosurgical intervention.

Conclusion

Although we could not just rely on clinical symptoms for decision-making about further radiologic assessment, but some of these clinical symptoms as mentioned above (PTV, PTS, LOC, and ear/nose bleeding) could be considered as clinical risk factors that help us to predict abnormal CT scans.

Conflict of Interests

Authors have no conflict of interest.

Acknowledgments

The authors would like to appreciate all children participating in this research and their families for their cooperation.

References

1. Jager TE, Weiss HB, Coben JH, Pepe PE. Traumatic brain injuries evaluated in U.S. emergency departments, 1992-1994. Acad Emerg Med 2000; 7(2): 134-40.
2. Savitsky EA, Votey SR. Current controversies in the management of minor pediatric head injuries. Am J Emerg Med 2000; 18(1): 96-101.
3. Kuppermann N. Pediatric head trauma: the evidence regarding indications for emergent neuroimaging. Pediatr Radiol 2008; 38(Suppl 4): S670-S674.
4. Palchak MJ, Holmes JF, Vance CW, Gelber RE, Schauer BA, Harrison MJ, et al. A decision rule for identifying children at low risk for brain injuries after blunt head trauma. Ann Emerg Med 2003; 42(4): 492-506.
5. Osmond MH, Klassen TP, Wells GA, Correll R, Jarvis A, Joubert G, et al. CATCH: a clinical decision rule for the use of computed tomography in children with minor head injury. CMAJ 2010; 182(4): 341-8.
6. Thomas KE, Parnell-Parmley JE, Haidar S, Moineddin R, Charkot E, BenDavid G, et al. Assessment of radiation dose awareness among pediatricians. Pediatr Radiol 2006; 36(8): 823-32.
7. Connors JM, Ruddy RM, McCall J, Garcia VF. Delayed diagnosis in pediatric blunt trauma. Pediatr Emerg Care 2001; 17(1): 1-4.
8. Hamilton M, Mrazik M, Johnson DW. Incidence of delayed intracranial hemorrhage in children after uncomplicated minor head injuries. Pediatrics 2010; 126(1): e33-e39.
9. Blackwell CD, Gorelick M, Holmes JF, Bandyopadhyay S, Kuppermann N. Pediatric head trauma: changes in use of computed tomography in emergency departments in the United States over time. Ann Emerg Med 2007; 49(3): 320-4.
10. Dorfman AL, Fazel R, Einstein AJ, Applegate KE, Krumholz HM, Wang Y, et al. Use of medical imaging procedures with ionizing radiation in children: a population-based study. Arch Pediatr Adolesc Med 2011; 165(5): 458-64.
11. Brenner D, Elliston C, Hall E, Berdon W. Estimated risks of radiation-induced fatal cancer from pediatric CT. AJR Am J Roentgenol 2001; 176(2): 289-96.
12. Brenner DJ. Estimating cancer risks from pediatric CT: going from the qualitative to the quantitative. Pediatr Radiol 2002; 32(4): 228-1.
13. Brenner DJ, Hall EJ. Computed tomography-an increasing source of radiation exposure. N Engl J Med 2007; 357(22): 2277-84.
14. Frush DP, Frush KS. The ALARA concept in pediatric imaging: building bridges between radiology and emergency medicine: consensus conference on imaging safety and quality for children in the emergency setting, Feb. 23-24, 2008, Orlando, FL - Executive Summary. Pediatr Radiol 2008; 38(Suppl 4): S629-S632.
15. Kuppermann N, Holmes JF, Dayan PS, Hoyle JD, Jr., Atabaki SM, Holubkov R, et al. Identification of children at very low risk of clinically-important brain injuries after head trauma: a prospective cohort study. Lancet 2009; 374(9696): 1160-70.
16. Maguire JL, Boutis K, Uleryk EM, Laupacis A, Parkin PC. Should a head-injured child receive a head CT scan? A systematic review of clinical prediction rules. Pediatrics 2009; 124(1): e145-e154.
17. Simon B, Letourneau P, Vitorino E, McCall J. Pediatric minor head trauma: indications for computed tomographic scanning revisited. J Trauma 2001; 51(2): 231-7.
18. Atabaki SM, Stiell IG, Bazarian JJ, Sadow KE, Vu TT, Camarca MA, et al. A clinical decision rule for cranial computed tomography in minor pediatric head trauma. Arch Pediatr Adolesc Med 2008; 162(5): 439-45.
19. Dunning J, Daly JP, Lomas JP, Lecky F, Batchelor J, Mackway-Jones K. Derivation of the children's head injury algorithm for the prediction of important clinical events decision rule for head injury in children. Arch Dis Child 2006; 91(11): 885-91.
20. Quayle KS, Jaffe DM, Kuppermann N, Kaufman BA, Lee BC, Park TS, et al. Diagnostic testing for acute head injury in children: when are head computed tomography and skull radiographs indicated? Pediatrics 1997; 99(5): E11.
21. Özsaraç M, Karçýoðlu Ö, Kuppermann N, Topaçoðlu H, Ayrik C, Kiyan S, et al. Clinical indicators of traumatic brain injury and skull fracture in pediatric head trauma patients. Turk J Emerg Med 2009; 9(4): 153-8.
22. Zhu H, Gao Q, Xia X, Xiang J, Yao H, Shao J. Clinically-important brain injury and CT findings in

pediatric mild traumatic brain injuries: a prospective study in a Chinese reference hospital. Int J Environ Res Public Health 2014; 11(4): 3493-506.
23. Peloso PM, von HH, Borg J. Mild traumatic brain injuries presenting to Swedish hospitals in 1987-2000. J Rehabil Med 2004; (43 Suppl): 22-7.
24. Willer B, Dumas J, Hutson A, Leddy J. A population based investigation of head injuries and symptoms of concussion of children and adolescents in schools. Inj Prev 2004; 10(3): 144-8.
25. Elgmark AE, Emanuelson I, Bjorklund R, Stalhammar DA. Mild traumatic brain injuries: the impact of early intervention on late sequelae. A randomized controlled trial. Acta Neurochir (Wien) 2007; 149(2): 151-9.
26. Munivenkatappa A, Deepika A, Prathyusha V, Devi I, Shukla D. Can an abnormal CT scan be predicted from common symptoms after mild head injury in children? J Pediatr Neurosci 2013; 8(3): 183-7.
27. Gulsen I, Ak H, Karadas S, Demir I, Bulut MD, Yaycioglu S. Indications of brain computed tomography scan in children younger than 3 years of age with minor head trauma. Emerg Med Int 2014; 2014: 248967.
28. Da DL, Andreola B, Facchin P, Gregolin M, Vianello A, Battistella PA. Characteristics of children with vomiting after minor head trauma: a case-control study. J Pediatr 2007; 150(3): 274-8.
29. Greenes DS, Schutzman SA. Clinical indicators of intracranial injury in head-injured infants. Pediatrics 1999; 104(4 Pt 1): 861-7.
30. Greenes DS, Schutzman SA. Clinical significance of scalp abnormalities in asymptomatic head-injured infants. Pediatr Emerg Care 2001; 17(2): 88-92.
31. Gruskin KD, Schutzman SA. Head trauma in children younger than 2 years: are there predictors for complications? Arch Pediatr Adolesc Med 1999; 153(1): 15-20.
32. Haydel MJ, Shembekar AD. Prediction of intracranial injury in children aged five years and older with loss of consciousness after minor head injury due to nontrivial mechanisms. Ann Emerg Med 2003; 42(4): 507-14.
33. Ratan SK, Pandey RM, Ratan J. Association among duration of unconsciousness, Glasgow Coma Scale, and cranial computed tomography abnormalities in head-injured children. Clin Pediatr (Phila) 2001; 40(7): 375-8.
34. Schunk JE, Rodgerson JD, Woodward GA. The utility of head computed tomographic scanning in pediatric patients with normal neurologic examination in the emergency department. Pediatr Emerg Care 1996; 12(3): 160-5.
35. Davis RL, Mullen N, Makela M, Taylor JA, Cohen W, Rivara FP. Cranial computed tomography scans in children after minimal head injury with loss of consciousness. Ann Emerg Med 1994; 24(4): 640-5.
36. Falimirski ME, Gonzalez R, Rodriguez A, Wilberger J. The need for head computed tomography in patients sustaining loss of consciousness after mild head injury. J Trauma 2003; 55(1): 1-6.
37. Dietrich AM, Bowman MJ, Ginn-Pease ME, Kosnik E, King DR. Pediatric head injuries: can clinical factors reliably predict an abnormality on computed tomography? Ann Emerg Med 1993; 22(10): 1535-40.
38. Homer CJ, Kleinman L. Technical report: minor head injury in children. Pediatrics 1999; 104(6): e78.
39. Klassen TP, Reed MH, Stiell IG, Nijssen-Jordan C, Tenenbein M, Joubert G, et al. Variation in utilization of computed tomography scanning for the investigation of minor head trauma in children: a Canadian experience. Acad Emerg Med 2000; 7(7): 739-44.
40. Ng SM, Toh EM, Sherrington CA. Clinical predictors of abnormal computed tomography scans in paediatric head injury. J Paediatr Child Health 2002; 38(4): 388-92.
41. Ramundo ML, McKnight T, Kempf J, Satkowiak L. Clinical predictors of computed tomographic abnormalities following pediatric traumatic brain injury. Pediatr Emerg Care 1995; 11(1): 1-4.
42. Rivara F, Tanaguchi D, Parish RA, Stimac GK, Mueller B. Poor prediction of positive computed tomographic scans by clinical criteria in symptomatic pediatric head trauma. Pediatrics 1987; 80(4): 579-84.
43. Sharma P, Dahiya RS, Dass B, Dewan Y, Arora AL. How important is history of unconsciousness in head injury patients? J Indian Med Assoc 2001; 99(2): 81-3.
44. Dias MS, Carnevale F, Li V. Immediate posttraumatic seizures: is routine hospitalization necessary? Pediatr Neurosurg 1999; 30(5): 232-8.
45. Saboori M, Ahmadi J, Farajzadegan Z. Indications for brain CT scan in patients with minor head injury. Clin Neurol Neurosurg 2007; 109(5): 399-405.
46. Dunning J, Batchelor J, Stratford-Smith P, Teece S, Browne J, Sharpin C, et al. A meta-analysis of variables that predict significant intracranial injury in minor head trauma. Arch Dis Child 2004; 89(7): 653-9.