

Research Article

The Preventive Effect of Atorvastatin on Paraquat-Induced Pulmonary Fibrosis in the Rats

Mohammad Javad Khodayar^{1,2*}, Milad Kiani¹, Ali Asghar Hemmati¹, Anahita Rezaie³, Mohammad Rahim Zerfatfard¹, Mohammad Reza Rashidi Nooshabadi¹, Mehdi Goudarzi¹

¹ Department of Pharmacology and Toxicology, School of Pharmacy, Ahvaz Jundishapur University of Medical Sciences, Ahvaz, Iran.

² Toxicology Research Center, Ahvaz Jundishapur University of Medical Sciences, Ahvaz, Iran.

³ Department of Pathology, Faculty of Veterinary Medicine, Shahid Chamran University, Ahvaz, Iran.

Article info

Article History:

Received: 29 September 2013

Revised: 1 February 2014

Accepted: 1 February 2014

ePublished: 10 August 2014

Keywords:

- Paraquat
- Pulmonary fibrosis
- Atorvastatin
- Rat

Abstract

Purpose: Pulmonary fibrosis is a potentially lethal inflammatory disease and there has been no effective medication for this progressive disease up to now. As a model, different therapeutic approaches have been applied for paraquat-induced pulmonary injury and fibrosis. Atorvastatin besides cholesterol-lowering effects possesses anti-inflammatory and anti-oxidant properties. The current study was designed to investigate the preventive anti-fibrotic effects of atorvastatin on paraquat-induced pulmonary fibrosis in rats.

Methods: The rats were randomly divided into five experimental groups. Group I, control group (saline), group II received a single oral dose of 20 mg/kg paraquat with no treatment and III, IV and V groups received atorvastatin at the doses of 10, 20, and 40 mg/kg/day orally one week before and three weeks after paraquat administration, respectively. The rats were sacrificed 21 days after paraquat. Lung hydroxyproline and serum levels of malondialdehyde (MDA) were determined and lung indices and semi-quantitative histopathological changes were evaluated.

Results: Paraquat could significantly increase the serum MDA and lung hydroxyproline levels. Elevated content of tissue hydroxyproline and serum levels of malondialdehyde induced by paraquat, attenuated by atorvastatin at the doses of 10, 20 and 40 mg/kg. Furthermore, histopathological findings and the amount of lung indices showed the beneficial preventive role of atorvastatin in rat pulmonary fibrosis induced by paraquat.

Conclusion: In conclusion, the present data show that atorvastatin alleviate the toxic effects of paraquat under the experimental circumstances and may be a useful agent in cases who are in contact or poisoned with paraquat.

Introduction

Pulmonary fibrosis may result from a variety of acute and chronic lung disorders. The great accumulation of matrix proteins such as collagen produced by fibroblasts and myofibroblasts, thicken and damage alveolar walls and reduce elasticity, widening of interstitial matrix and development of lung fibrosis.¹ Although specific treatments for fibrotic lung diseases are not yet available, control and prevention of inflammatory events might delay progress of the fibrotic events. Corticosteroids are usually administered to control the inflammation in fibrotic lungs; however, the useful effects of these agents are not well established.² The progression of pulmonary fibrosis is closely related to a complicated network consisting of many cytokines, chemical mediators, growth factors and biophysical peptides derived from inflammatory immune cells, alveolar type II cells and endothelial cells.³

Paraquat (C₁₂ H₁₄ N₂), a bipyridyl and non-selective quaternary nitrogen herbicide, is commonly used all

around the world. Paraquat a highly toxic herbicide causes fatal pulmonary damage. Although liver, kidney, heart and central nervous system are affected, lung damage and pulmonary fibrosis are the most widespread injuries and the usual causes of death. Lung tissue and particularly the type II pneumocytes accumulate paraquat by a selective and active polyamine uptake procedure.^{4,5}

The mechanism of paraquat toxicity has not been fully understood. The main potential mechanism is producing the superoxide radicals.^{6,7} The chemical cascades leading to the reduction of paraquat and the generation of free radicals and lipid peroxidation may create lethal lesions associated with intra-alveolar fibrosis resulting in lung failure.^{8,9} The pulmonary toxicity of paraquat occurs in two different phases. The first is a damage and demolition of alveolar epithelial cells causing edema and hemorrhage. The second is to infiltrate myofibroblasts into the alveolar spaces and septa and differentiation in fibroblasts by producing

*Corresponding author: Mohammad Javad Khodayar, Tel: +98 611 3738378, Email: khodayar-mj@ajums.ac.ir

©2014 The Authors. This is an Open Access article distributed under the terms of the Creative Commons Attribution (CC BY), which permits unrestricted use, distribution, and reproduction in any medium, as long as the original authors and source are cited. No permission is required from the authors or the publishers.

collagen.^{10,11} At present no specific antidote or effective treatment is proposed for paraquat toxicity and poisoning. Since there are no known pharmacological antidote for paraquat, the management of paraquat poisoning has been predominantly limited either to decrease its absorption or to increase its elimination.¹² Currently different treatment strategies that prevent or reverse the lipid peroxidation at the cellular level and reduce the pulmonary collagen synthesis had been reported.^{13,14}

Statins, which are HMG-CoA reductase inhibitors, belong to a class of drugs that lowers the level of cholesterol in the blood. Statins may have also antifibrotic function. Statins block hydroxymethylglutaryl-coenzyme A reductase (HMG-CoA reductase), which takes part in liver synthesis of cholesterol. Recent research shows that statins reduce inflammation. Reduction of inflammation by statins is independent of statins ability to reduce cholesterol. Furthermore, anti-inflammatory effects of statins can be seen as early as two weeks after starting statin treatment.^{15,16}

In recent years, several studies have shown these positive effects of statins to be due both to their lipid lowering and to anti-inflammatory effect.¹⁷ Positive results in experimental efforts have been obtained through the anti-inflammatory efficacy of statins in numerous respiratory disease models such as smoking-induced emphysema, asthma, Idiopathic Pulmonary Fibrosis (IPF), pulmonary hypertension, acute lung injury and lung transplantation.

Materials and Methods

Animals

Thirty female Sprague–Dawley rats, 8 weeks old, weighting 200 ± 25 g were purchased from the experimental research center, medical science university of Jundishapur (Iran, Ahvaz). Rats were housed in a specific cage in 24 h light/dark cycle and allowed with free access to water and food. All the ethical issues were considered based on the Ahvaz Medical University Ethical Protocols (AMUEP) on animal experiments.

Reagents

Atorvastatin was obtained from Exir pharmaceutical manufacturing company (Borujerd, Iran). Paraquat (methyl viologen) and other chemicals were purchased from Sigma Chemical Co. (St Louis, MO, USA).

Experiment Protocols

To investigate whether atorvastatin modulates paraquat-induced pulmonary fibrosis, the rats were randomly divided into five experimental groups (six rats in each group). Group I, control group (saline), group II received a single oral dose of 20 mg/kg paraquat with no treatment and III, IV and V groups received atorvastatin at the doses of 10, 20, and 40 mg/kg/day orally one week before and three weeks after paraquat administration,

respectively. The rats were sacrificed 21 days after paraquat.

Body Weight and Lung Index

In the course of the experiment, the body weight of rats was measured every 7 days. After sacrifice, the lung index was expressed as the ratio of wet lung weight (mg) to body weight (g).

Lipid peroxidation assay

The serum malondialdehyde (MDA) levels as a measurement of oxidative stress were determined by the method described by Hemmati.¹⁸ Values obtained were compared with a series of standard Solutions (1, 1, 3, 3-tetraethoxypropane). The serum samples were obtained by collecting 1ml blood from the left ventricle, centrifuging at 1000g for 5min, and diluting 20 times with phosphate buffer solution (pH = 7.4). Results were expressed as $\mu\text{mol/L}$.

Histopathological examination

Rat lungs on day 21 after paraquat administration were inflated with a buffered 10% formalin solution for 24 h and embedded in paraffin. Sections (3 μm) were stained with hematoxylin and eosin for histological examination. The Ashcroft score was used for semi-quantitative assessment of fibrotic changes. The severity of fibrotic changes in each histological section of the lung was assessed as the mean score of severity from observing microscopic fields. Twenty five fields in each rat lung section were analyzed. After examination of the whole fields of the section, the mean of the scores from all fields was considered as the fibrotic score. The entire lung section was reviewed at a magnification of $\times 100$. A score ranging from zero (normal lung) to eight (total fibrosis) was assigned. The mean score of all fields was taken as a fibrosis score of that lung section. Criteria for grading pulmonary fibrosis were as follows: A grade 0 normal lung; 1=minimal fibrosis thickening of alveolar or bronchial walls; 2–3=moderate thickening of the walls without obvious damage to the lung architecture; 4–5=increased fibrosis with definite damage to lung architecture and formation of fibrotic bands or small fibrotic mass; 6–7=severe distortion of structure and large fibrotic are as; “honeycomb lung” was placed in this category and grade 8 indicates a total fibrotic change of the field. The mean score of all fields was taken as the fibrosis score of that lung section.¹⁹

Hydroxyproline assay

The lung hydroxyproline of the left lung was measured using a colorimetric assay on day 21 after paraquat.²⁰ In brief, the minced left lung lobes were homogenized in 6 molar HCl and hydrolyzed for five hours at 130°C. The pH was adjusted to 6.5–7.0 with NaOH, and the sample volume was adjusted to 30 ml with distilled water. The sample solution (1.0 ml) was mixed with 1.0 ml of chloramine T solution (0.05 mol/L), and then

the mixture was incubated at room temperature for 20 minutes. When 1.0 ml of 20% dimethyl benzaldehyde solution was added, the mixture was incubated at 60°C for 20 minutes. The absorbance of each sample at 550 nm was measured. The results were calculated as mg hydroxyproline per g wet lung weight using hydroxyproline standards.

Statistical analysis

Data were expressed as mean±SEM. Statistical analysis was carried out by analysis of variance (ANOVA) followed by Tukey's post hoc tests. All analyses were made using the SPSS version 16 and the probability value of less than 0.05 was considered as statistically significant.

Results

Lung indices

The lung index (wet lung weight/body weight) in the control group was significantly lower compared with the paraquat group on day 28. However, the rats received atorvastatin (10 and 20 mg/kg) significantly lower lung index compared with the paraquat group (Figure 1).

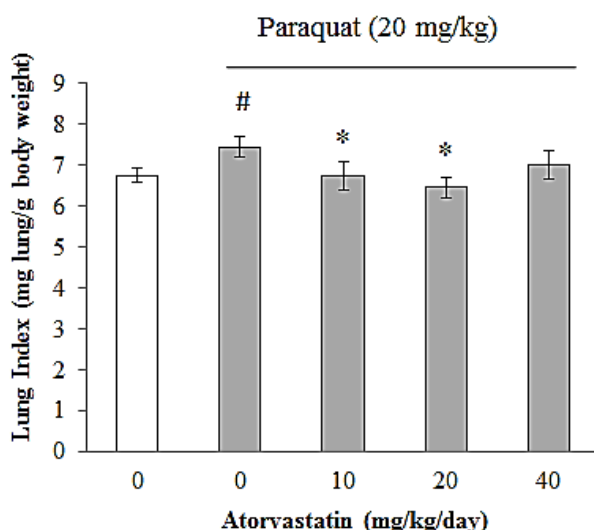


Figure 1. Effect of atorvastatin pretreatment at the doses of 10, 20 and 40 mg/kg on lung index of rats in paraquat-induced pulmonary fibrosis. Each column represents mean lung index ± SEM. # A significant increase of the lung index in the paraquat group in comparison with the control group ($P < 0.05$). * A significant decrease of the lung index in atorvastatin groups at the doses of 10 and 20 mg/kg in comparison with the paraquat group ($P < 0.05$).

Assessment of lung fibrosis by measurement of hydroxyproline

Lung fibrosis was assessed by measuring the hydroxyproline content in lungs as an index of collagen accumulation. A comparison of hydroxyproline contents among the 5 groups was shown in Figure 2. Paraquat treatment produced a significant increase in the hydroxyproline levels. This increment was prevented by atorvastatin.

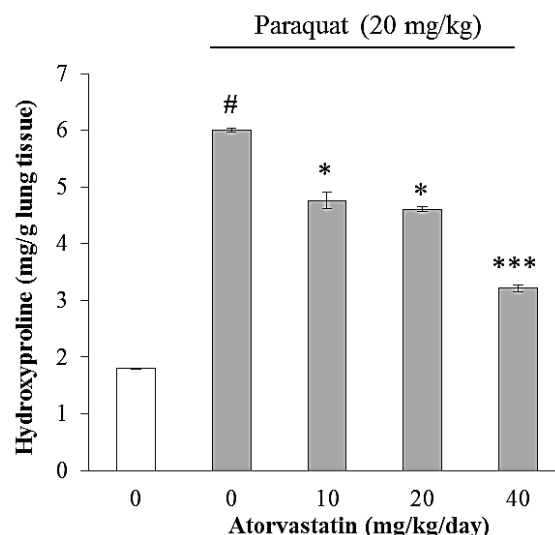


Figure 2. Effect of pretreatment with atorvastatin at the doses of 10, 20 and 40 mg/kg on hydroxyproline content in the lungs of rats with pulmonary fibrosis. Each column represents mean ± SEM of hydroxyproline; a significant increase of hydroxyproline in paraquat group in comparison with the control group ($^{\#}P < 0.05$); a significant decrease of hydroxyproline in atorvastatin groups in comparison with the paraquat group ($^*P < 0.05$ and $^{***}p < 0.001$).

The analysis of oxidative stress marker

A significant rise was observed in MDA level in serum of rat exposed to paraquat which is an index of lipid peroxidation, when compared with the control group ($^{\#}p < 0.001$). As shown in Figure 3, the decrease in MDA level was observed in pretreated rats by atorvastatin ($^*p < 0.05$ and $^{***}p < 0.001$).

The light microscopic findings

Photomicrographic evaluation of pulmonary fibrosis by infiltration of fibroblast, inflammatory cells and extracellular matrix showed grade 0 for control and grade 8 more prominent for paraquat group. The rat pretreated by atorvastatin showed grade 6-7 for the dose of 10 mg/kg of atorvastatin and grade 4-5 more evident for the lung photomicrographs in the dose of 20 and 40 mg/kg of atorvastatin (Figure 4).

Discussion

This study inquired whether pretreatment and continuing treatment with atorvastatin might attenuate pulmonary fibrosis following paraquat administration in rat. Because inflammation and fibrosis are the two determinants of the development of pulmonary fibrosis, potentially beneficial anti-inflammatory and anti-fibrotic effects of atorvastatin on paraquat induced pulmonary fibrosis were measured. In this study, atorvastatin had the following effects in paraquat-induced pulmonary fibrosis as a popular model of human pulmonary fibrosis: (a) attenuating the increase of inflammatory cells and hydroxyproline and collagen content in lung tissue, (b) alleviation of paraquat-induced increases in the MDA levels that may be through an increase in antioxidant enzyme activities in

the damaged lung tissue of rats. Antioxidant treatments have been extensively investigated in human IPF and paraquat-induced lung fibrosis in rat. The rationale for this approach presumes that the progressive fibrosis that characterized IPF results from chronic persistent inflammation. The existence of chronic inflammation in lung tissue ultimately leads fibrosis. However, aggressive suppression of this inflammation will block the subsequent accumulation of matrix proteins such as collagen formation, proliferation of fibroblasts and recruitment of inflammatory cells. Reduced MDA level of rats pretreated with atorvastatin may suggest the antioxidant activity of the drug. It has been reported that statins exert anti-inflammatory effects in numerous tissues via the activation of peroxisome proliferator-activated receptors (PPARs), which regulates important cellular functions, such as glucose and lipid catabolism, cellular differentiation, proliferation and survival.²¹⁻²³ Anti-proliferative and pro-apoptotic activity of atorvastatin has been viewed as a promising therapeutic target for bladder cancer.²⁴ Furthermore, the effects of statins, namely of atorvastatin, seem to be potentiated by cyclooxygenase (COX) -2 inhibitors.²⁵ These data suggest the role of inflammation in lung fibrosis and the putative relevance of preventive strategies based on anti-inflammatory activity, such as demonstrated by atorvastatin in the present study. This observation may have significance for the present study because of pathobiological similarity between high altitude pulmonary edema and paraquat-induced lung fibrosis in which free radical formation may play an important role. Possible mechanism of the preventive role of atorvastatin on high altitude pulmonary edema seems to be its free radical scavenging activity.

Conclusion

The findings of the current study illustrate that paraquat administration resulted in lung fibrosis in rats via increased oxidative stress and atorvastatin significantly prevented the fibrosis events through its potent free radical scavenging and antioxidant properties. The data suggest that atorvastatin is a highly promising agent in protecting early lung tissue damage induced by paraquat exposure or in the treatment of IPF.

Acknowledgments

This paper was extracted from Milad Kiani's Pharm.D thesis that was submitted in the School of Pharmacy of Ahvaz Jundishapur University of Medical Sciences and financially supported by a grant of Toxicology Research Center of this university.

Conflict of Interest

There is no conflict of interest to be reported.

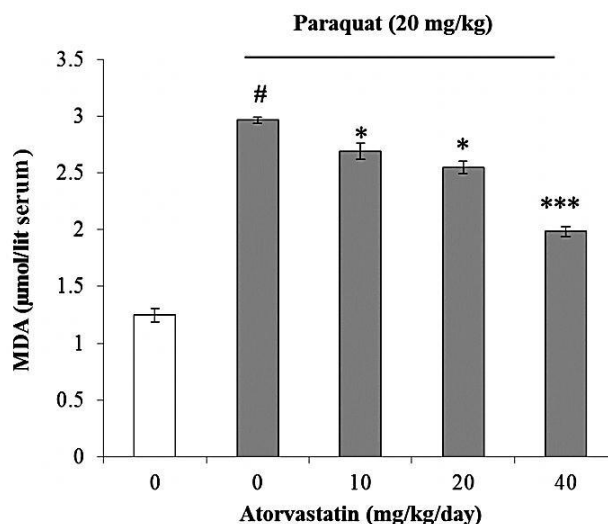


Figure 3. Effect of pretreatment with atorvastatin at the doses of 10, 20 and 40 mg/kg on serum MDA of rats with pulmonary fibrosis. Each column represents mean MDA \pm SEM; a significant increase of MDA in paraquat group in comparison with the control group ($^{\#}P < 0.05$); a significant decrease of MDA in atorvastatin treated groups in comparison with the paraquat group ($^*P < 0.05$ and $^{***}p < 0.001$).

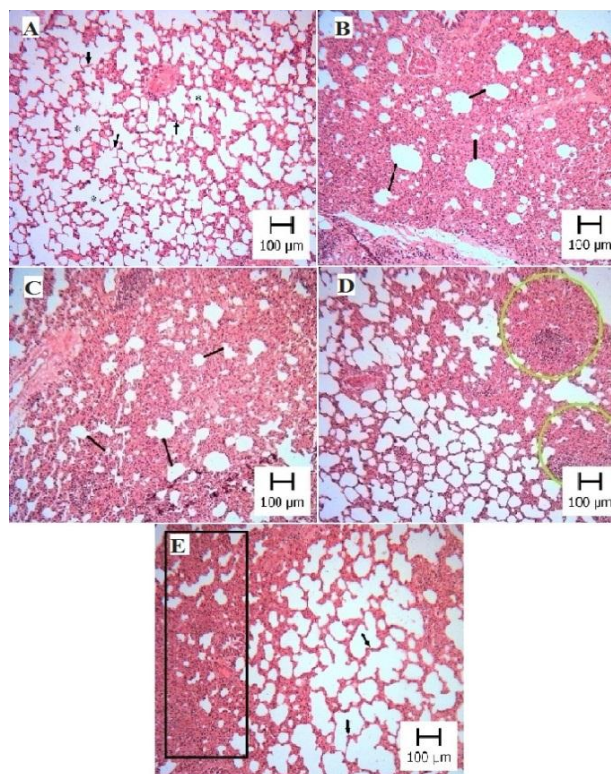


Figure 4. The figures are representatives of the lungs from animals in each treatment group. Lung tissues were stained 21 days after administration of paraquat in saline with H&E. Appearance of rat lungs in different groups: (A) control (B) paraquat (C) paraquat treated with 10 mg/kg atorvastatin (D) paraquat treated with 20 mg/kg atorvastatin and (E) paraquat treated with 40 mg/kg atorvastatin. Lung parenchyma of control is well-preserved and intact. Extensive interstitial infiltration and fibrosis showing in group (B). A marked prevention of the paraquat-induced histological changes was seen in the rat lungs in groups (D) and (E).

References

1. Green FH. Overview of pulmonary fibrosis. *Chest* 2002;122(6 Suppl):334S-9S.
2. Kroegel C, Mock B, Hengst U, Reissig A. Interferon-gamma-1b: therapeutic option in advanced idiopathic pulmonary fibrosis? *Respiration* 2004;71(6):656-7.
3. Yao HW, Zhu JP, Zhao MH, Lu Y. Losartan attenuates bleomycin-induced pulmonary fibrosis in rats. *Respiration* 2006;73(2):236-42.
4. Rose MS, Smith LL, Wyatt I. Evidence for energy-dependent accumulation of paraquat into rat lung. *Nature* 1974;252(5481):314-5.
5. Forman HJ, Aldrich TK, Posner MA, Fisher AB. Differential paraquat uptake and redox kinetics of rat granular pneumocytes and alveolar macrophages. *J Pharmacol Exp Ther* 1982;221(2):428-33.
6. Smith LL. The toxicity of paraquat. *Adverse Drug React Acute Poisoning Rev* 1988;7(1):1-17.
7. Aldrich TK, Fisher AB, Cadenas E, Chance B. Evidence for lipid peroxidation by paraquat in the perfused rat lung. *J Lab Clin Med* 1983;101(1):66-73.
8. Carre P, Leophonte P. Cytokines and pulmonary fibroses. *Rev Mal Respir* 1993;10(3):193-207.
9. Melchiorri D, Reiter RJ, Sewerynek E, Hara M, Chen L, Nistico G. Paraquat toxicity and oxidative damage. Reduction by melatonin. *Biochem Pharmacol* 1996;51(8):1095-9.
10. Vijeyaratnam GS, Corrin B. Experimental paraquat poisoning: a histological and electron-optical study of the changes in the lung. *J Pathol* 1971;103(2):123-9.
11. Smith LL, Rose MS. A comparison of the effects of paraquat and diquat on the water content of rat lung and the incorporation of thymidine into lung DNA. *Toxicology* 1977;8(2):223-30.
12. Suntres ZE, Hepworth SR, Shek PN. Protective effect of liposome-associated alpha-tocopherol against paraquat-induced acute lung toxicity. *Biochem Pharmacol* 1992;44(9):1811-8.
13. Shahar E, Keidar I, Hertzeg E, Barzilay Z. Effectiveness of vitamin E and colchicine in amelioration of paraquat lung injuries using an experimental model. *Isr J Med Sci* 1989;25(2):92-4.
14. Kojima S, Miyazaki Y, Honda T, Kiyozumi M, Shimada H, Funakoshi T. Effect of L-cystine on toxicity of paraquat in mice. *Toxicol Lett* 1992;60(1):75-82.
15. Lardizabal JA, Deedwania PC. Benefits of statin therapy and compliance in high risk cardiovascular patients. *Vasc Health Risk Manag* 2010;6:843-53.
16. Tousoulis D, Charakida M, Stefanadi E, Siasos G, Latsios G, Stefanadis C. Statins in heart failure. Beyond the lipid lowering effect. *Int J Cardiol* 2007;115(2):144-50.
17. Greenwood J, Steinman L, Zamvil SS. Statin therapy and autoimmune disease: from protein prenylation to immunomodulation. *Nat Rev Immunol* 2006;6(5):358-70.
18. Hemmati AA, Nazari Z, Samei M. A comparative study of grape seed extract and vitamin E effects on silica-induced pulmonary fibrosis in rats. *Pulm Pharmacol Ther* 2008;21(4):668-74.
19. Ashcroft T, Simpson JM, Timbrell V. Simple method of estimating severity of pulmonary fibrosis on a numerical scale. *J Clin Pathol* 1988;41(4):467-70.
20. Woessner JF Jr. The determination of hydroxyproline in tissue and protein samples containing small proportions of this imino acid. *Arch Biochem Biophys* 1961;93:440-7.
21. Balakumar P, Mahadevan N. Interplay between statins and PPARs in improving cardiovascular outcomes: a double-edged sword? *Br J Pharmacol* 2012;165(2):373-9.
22. Paumelle R, Blanquart C, Briand O, Barbier O, Duhem C, Woerly G, et al. Acute antiinflammatory properties of statins involve peroxisome proliferator-activated receptor-alpha via inhibition of the protein kinase C signaling pathway. *Circ Res* 2006;98(3):361-9.
23. Moraes LA, Piqueras L, Bishop-Bailey D. Peroxisome proliferator-activated receptors and inflammation. *Pharmacol Ther* 2006;110(3):371-85.
24. Mansure JJ, Nassim R, Kassouf W. Peroxisome proliferator-activated receptor gamma in bladder cancer: a promising therapeutic target. *Cancer Biol Ther* 2009;8(7):6-15.
25. Zheng X, Cui XX, Avila GE, Huang MT, Liu Y, Patel J, et al. Atorvastatin and celecoxib inhibit prostate PC-3 tumors in immunodeficient mice. *Clin Cancer Res* 2007;13(18 Pt 1):5480-7.